

ECG Report

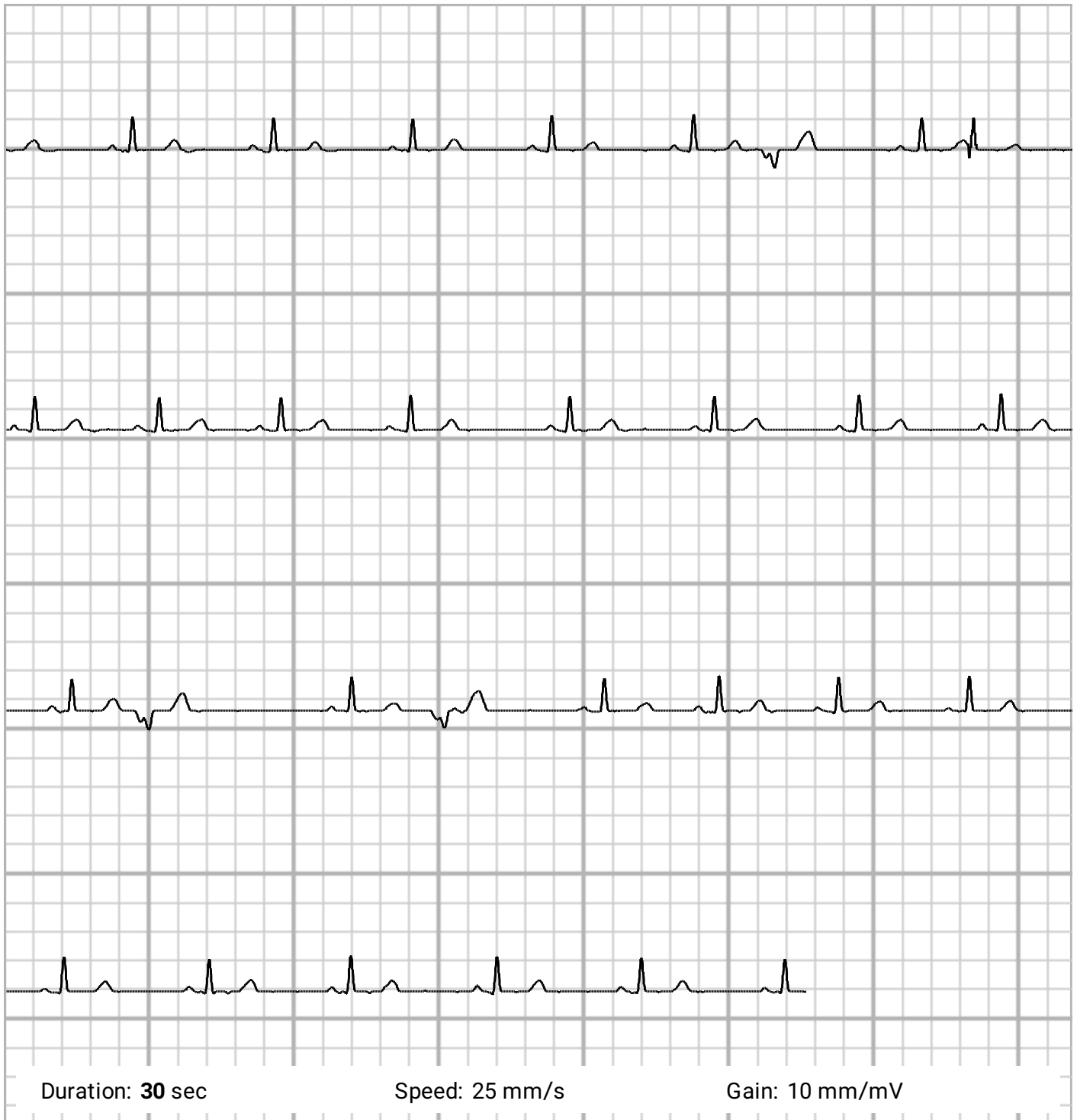
96 SonoHealth

Patient: Norsha

Tip: Missed Beat, Bradycardia

Recorded: 06/22/2019 4:52 pm

Heart Rate: 52 bpm



HR: 52 bpm, Missed Beat, Bradycardia